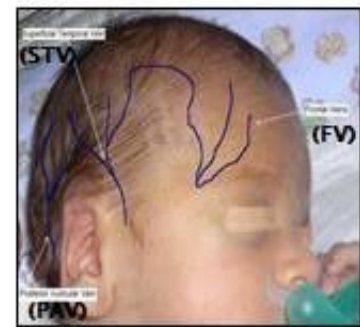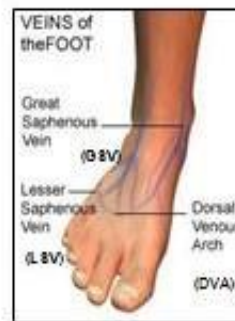
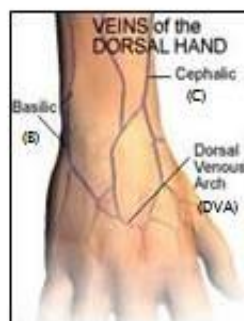
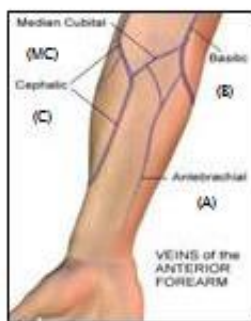


VISUAL INFUSION PHLEBITIS SCORE (V.I.P SCORE)			
SITE OBSERVATION	SCORE	SIGNS OF PHLEBITIS	ACTION
IV Site appears healthy	0	No signs of phlebitis	OBSERVE CANNULA
One of the following signs is evident: 1. Pain near IV site (Pain score 1-3). May not require analgesic. 2. Slight redness near IV site	1	Possibly first signs of phlebitis	OBSERVE / RESITE CANNULA
Two of the following signs are evident: 1. Pain at IV site - Moderate pain (Pain Score 4-6) Interferes with activities. 2. Redness near IV site 3. Swelling	2	Early stage of phlebitis	RESITE CANNULA
ALL of the following signs evident: 1. Pain along path of cannula (Pain Score 4-6) Interferes with concentration. 2. Redness around site 3. Swelling	3	Medium stage of phlebitis	RESITE CANNULA CONSIDER TREATMENT
ALL of the following signs evident and extensive: 1. Pain along path of cannula (Pain Score 7-9) Interferes with basic needs. 2. Redness around site 3. Swelling 4. Palpable Venous Cord	4	Advanced stage of phlebitis the start of thrombophlebitis	RESITE CANNULA CONSIDER TREATMENT
ALL of the following signs evident and extensive: 1. Pain along path of cannula (Pain Score 10) Bedrest required. 2. Redness around site 3. Swelling 4. Palpable venous cord 5 .Pyrexia	5	Advanced stage of thrombophlebitis	INITIATE TREATMENT RESITE CANNULA

Adapted from Andrew Jackson 1998

COMMON VEINS USE FOR SETTING IV LINES



ABBREVIATION					
HAND		LEG		HEAD	
A	Antebrachial	GSV	Great Saphenous Vein	STV	Superficial Temporal Vein
B	Basalic	LSV	Lesser Saphenous Vein	PWV	Posterior Auricular Vein
C	Cephalic	DVA	Dorsal Venous Arch	FV	Frontal Vein
MC	Median Cubital				
DVA	Dorsal Vein Arch				